

3D photography in facial rejuvenation

The term ageing is widely used to denote a series of changes that are clinically observed over time.

Throughout the ageing process, the cell renewal capacity becomes slower. The fibroblast, which is the main cell of the dermis, undergoes a drastic reduction in number, as well as an important impairment in function, with a significant decrease in the synthesis of collagen and elastic fibres, favouring the installation of cutaneous atrophy and sagging, with accentuation of the folds of the facial contour.

In addition to skin alterations, important changes also occur in subcutaneous tissue (SCT). Adipocytes lose volume by compromising the facial lining, giving the face a more skeletal appearance, with greater contrast between protrusions and depressions. In parallel, the connective tissue which structures the SCT undergoes important changes, favouring the installation of sagging along with the accentuation of the nasolabial folds, the 'marionette lines' and overall impairment of the facial contour.

If skin and SCT changes were not enough, significant muscle changes also occur on the face during ageing. Muscle groups, such as the upper lip elevator, greater and lesser zygomatics, as well as laryngeal muscles, start to be affected and to present damage in terms of tonus, trophism and function, contributing to the installation of flaccidity, facial skeletonisation and impairment of loco-regional metabolism, intensifying the suffering of the superjacent areas.

Listening to patient complaints and expectations is very important when designing a comprehensive facial rejuvenation program.

Physical examination is an essential part of patient assessment. Identifying and listing the changes mentioned above is fundamental so that the patient can better understand their needs, which can ultimately facilitate compliance to the proposed treatments.

3D photodocumentation can potentially be an essential tool, not only to better understand the ageing process, but also to help define protocols to restore facial harmony. With recent technological advances, physicians are able to capture the 3D images with portable and highly versatile cameras which fit flawlessly into their consultation workflow. The Quantificare suite we use to analyse the 3D images captured by these cameras is intuitive and highly informative, providing a huge range of data.

For skin evaluation, the SkinCare module provides analysis of wrinkles, pores, oiliness, cutaneous texture, roughness, vascular and pigmentary changes, allowing the physician to obtain evidence and measurements of significant changes to consider during the physical examination. For subcutaneous tissue evaluation, the tools are available to allow the analysis of the volumetric deficits, the

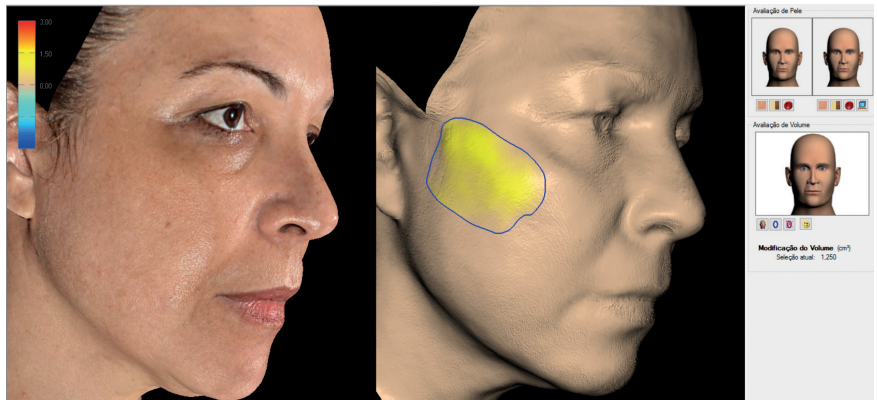


Figure 1: Measurement of the volume injected in a patient submitted to filling with hyaluronic acid in the malar and mentonian region (non-cross-linked hyaluronic acid 13,5mg/mL + mannitol 0,9%, 1,5cc per side).

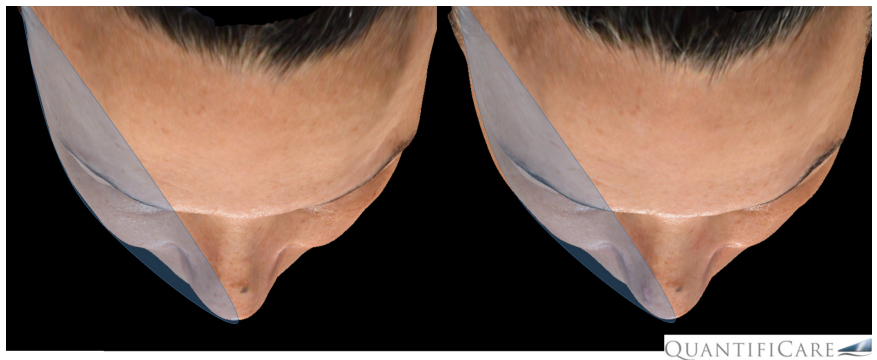


Figure 2: Cranial-caudal view of a patient submitted to filling with hyaluronic acid in malar and mentonian areas (non-cross-linked hyaluronic acid 13,5mg/mL + mannitol 0,9%, 1,5cc per side). Note the changing in volumetry of the patient's malar region, with a more uniform contour and smoother transition in the signaled area.

measurement of the importance of folds, as well as the influences of this anatomic plane in the facial contour.

In addition to assisting in the best evaluation, the 3D simulation tool enables the elaboration of more assertive treatment protocols and the clear understanding and compliance of the patients. The 3D photodocumentation can be used as a control parameter in the evaluation of the clinical improvement and the effectiveness of the treatments used.

Standardised photography is fundamental for an unbiased evaluation of results. An image which is captured without paying close attention to surrounding lighting, background, focus and distance can potentially compromise a post-procedure evaluation. With the capabilities of the 3D camera, many of these problems are solved along with the possibility to evaluate angles and positions which cannot be viewed using traditional photography techniques.

The use of 3D technology facilitates communication with patients, making even small changes in injectable treatments visible.

In our experience, Quantificare's 3D LifeViz system has proved to be an important tool to assist in facial evaluation and in the elaboration of more effective facial harmony restoration protocols and has helped to facilitate communication with patients.

AUTHORS

Fabio Lopes Saito,

Member of The Brazilian Society of Plastic Surgery, Member of American Society of Plastic Surgeons.

Ricardo Frota Boggio MD, PhD,

Member of The Brazilian Society of Plastic Surgery, Member of American Society of Plastic Surgeons, Member of Interatlantic Society of Aesthetic Plastic Surgery.

E: drboggio@clinicaboggio.com.br

Aneta Hionia Vassiliadis,

Member of The Brazilian Society of Plastic Surgery, Member of American Society of Plastic Surgeons.

Audrey Katherine Worthington,

SBCP Member, SBLMC Director, Fellow in Plastic Surgery, Free University Amsterdam.

Eliza Minami,

Professor of Operatory Technique and Experimental Surgery, UNIFESP, Member of The Brazilian Society of Plastic Surgery, Member of The Craniomaxillofacial Brazilian Society.

Priscila Arruda Bruno,

Cosmiatry Professor, FMABC, Member of The Brazilian Society of Plastic Surgery, Member of American Society of Plastic Surgeons.

Declaration of competing interests: Fabio Lopes Saito is a medical consultant for Allergan.