

Single session of 1064nm picosecond laser for ephelides

BY WONG YEUT SUN

Ephelides is a common pigmented problem which can appear on all skin types. Ephelides treatment usually involves 532 nm Nd:YAG laser and comes with a certain period of downtime and side-effects such as post-inflammatory hyperpigmentation.

With the new StarWalker® PQX which has highest peak power of 2.7 GW and 300 picoseconds we can safely clear most of the ephelides in single session, utilising 1064 nm instead of the 532 nm wavelength, without worrying about side-effects.

Patient selection

This treatment approach can be performed on all skin types, however, a lower fluence and number of stackings should be considered to avoid any unwanted side-effects. This protocol is especially useful for those wanting to avoid downtime, i.e. scab forming over their existing ephelides. The following case has been chosen to demonstrate the techniques and procedures involved in using this protocol to treat ephelides.

Case report

The patient is a 37-year-old with Fitzpatrick skin type II who presented with ephelides on her cheeks and periorbital area. She visited our clinic wanting to lighten the pigmentation with no downtime. With the patient's need in mind, 1064 nm picosecond laser was used in this treatment. The figures present her case before treatment and one month after the procedure.

Preparation

The patient's face was cleansed with make-up remover and foam cleanser prior to a photography session with a VISIA® skin analysis machine (Canfield). Then, topical anaesthetic cream (prilocaine 2.5%, lidocaine 2.5%) was applied for 20 minutes before being washed off and wiped clean.

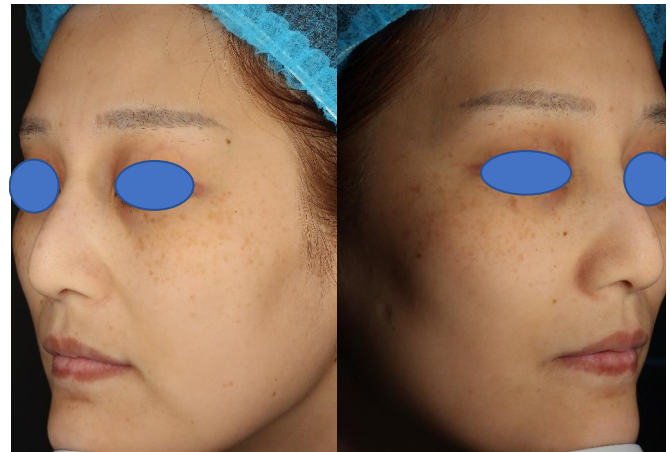
Treatment

The first step of treatment is to target the freckles by using the black handpiece, spot size 4mm, fluence 3.0J/cm², frequency 2 Hz. Two to three were done on the freckles. The pain from the laser was reported as mild and tolerable by the patient. The endpoint is lightening of the pigmentation.

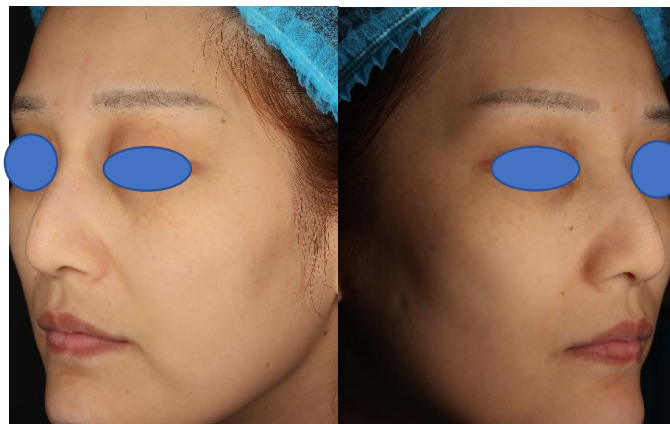
The second step of treatment is to target other areas by using the same handpiece, spot size 8mm, fluence 0.7J/cm², frequency 3 Hz, with multiple passes to achieve toning of the skin colour.

Post-treatment care

Moisturiser and sunscreen were applied to the patient after treatment. There was no redness or swelling after the procedure, thus the patient carried on with her social and work life without worrying about any side-effect from the laser. The patient was advised to avoid long periods of sun exposure.



Before



After

Results

The patient came back for a follow-up after one month and was satisfied with the results. No complications were observed. This case demonstrates that 1064 nm picosecond laser is an efficient way to achieve lightening of ephelides with no downtime involved.

AUTHOR



Wong Yeut Sun,

Aesthetic Dermatologist, DV Prestige, Bukit Jalil, Malaysia.

Declaration of competing interests:
None declared.